A:ECG Intermediate Session Quiz

Questions: 15
Pass: 70%

1. The intrinsic rate of the SA node is typically
   A. between 40 and 100 beats per minute
   B. between 60 and 100 beats per minute
   C. between 20 and 60 beats per minute
   D. between 100 and 150 beats per minute

2. Which statement about electrolytes and cardiac conduction is the most correct:
   A. The main electrolytes involved in cardiac conduction and the generation of the cardiac action potential are sodium, potassium, calcium, and magnesium.
   B. The main electrolytes involved in cardiac conduction and the generation of the cardiac action potential are sodium, potassium, chloride, and magnesium.
   C. The main electrolytes involved in cardiac conduction and the generation of the cardiac resting potential are sodium, potassium, calcium, and magnesium.
   D. The main electrolytes involved in cardiac conduction and the generation of the cardiac resting potential are sodium, potassium, chloride, and magnesium.

3. The intrinsic firing rate of the Purkinje fibers is
   A. 0 to 40 beats per minute
   B. 40 to 60 beats per minute
   C. 20 to 50 beats per minute
   D. 20 to 40 beats per minute

4. What is the most common type of ectopic beat?
   A. Premature Junctional Contraction (PJC)
   B. Premature Ventricular Contraction (PVC)
   C. Sinus arrhythmia
   D. Premature Atrial Contraction (PAC)

5. What is the primary characteristic of a PAC on an ECG?
   A. Early, abnormal P wave
   B. Early, wide QRS complex
   C. A shortened PRI
   D. Long PR interval

6. What is a distinguishing feature of a PJC on an ECG?
   A. Wide QRS complex with a normal P wave
   B. Absent P wave with a narrow QRS
   C. Inverted P wave before or after the QRS complex
   D. Prominent U wave

Rescue Me Nursing

7. Which of the following accurately distinguishes unifocal PVCs from multifocal PVCs on an ECG?

A. Unifocal PVCs have a variable QRS morphology, while multifocal PVCs have a consistent QRS morphology.
B. Unifocal PVCs originate from a single ectopic focus in the ventricles, leading to similar QRS morphologies, while multifocal PVCs originate from multiple ectopic foci, resulting in varying QRS morphologies.
C. Unifocal PVCs are characterized by a consistent PR interval, while multifocal PVCs have an irregular PR interval.
D. Unifocal PVCs present with narrow QRS complexes, while multifocal PVCs have wide QRS complexes.

8. A first-degree heart block would be expected to produce a PRI of:

A. Less than .20 seconds
B. The P wave will continue to conduct with no correlation with the narrow QRS
C. The PRI is different with each conduction
D. Greater than .20 seconds

9. What is the ECG tracing?



A. Second-degree type 2 heart block
B. Complete heart block
C. Idioventricular rhythm with a first-degree heart block
D. Mobitz type 1 heart block

10. What is the ECG interpretation?

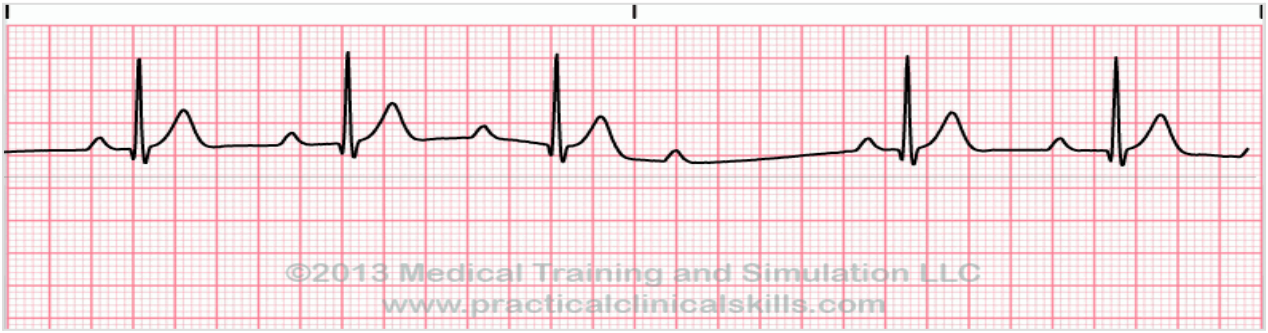

A. Normal sinus rhythm with first-degree heart block
B. A Wenckebach block
C. A Mobitz Type II

D. Complete heart block

11. What is the ECG interpretation?



A. Sinus tachycardia with PJC
B. Sinus tachycardia with PAC
C. Normal sinus rhythm with PJC
D. Normal sinus rhythm with PAC

12. What is the ECG interpretation?



A. Supraventricular tachycardia with PVCs
B. NSR with multifocal PVCs
C. Sinus tachycardia with unifocal PVCs
D. Atrial flutter with unifocal PVCs

13. What is the ECG interpretation?

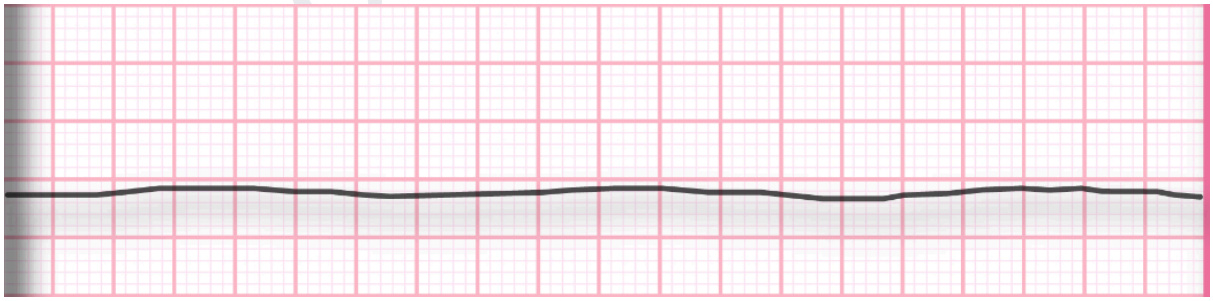

A. Sinus Block
B. Asystole
C. Ventricular fibrillation
D. Atrial fibrillation

14. What is the ECG interpretation? The rate is 120.

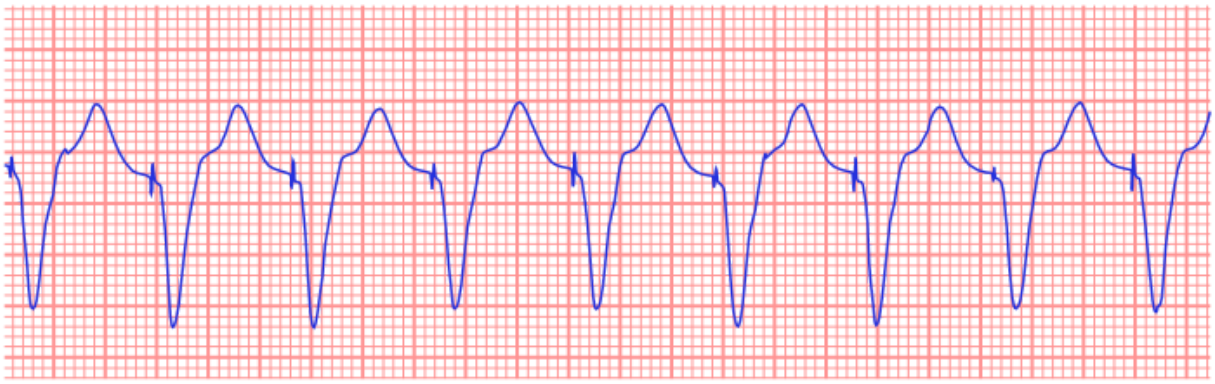

A. SVT with pacer capture
B. Ventricular tachycardia
C. Idioventricular with pacemaker mediation
D. Pacemaker-mediated tachycardia

15. What is the 12-lead ECG interpretation?

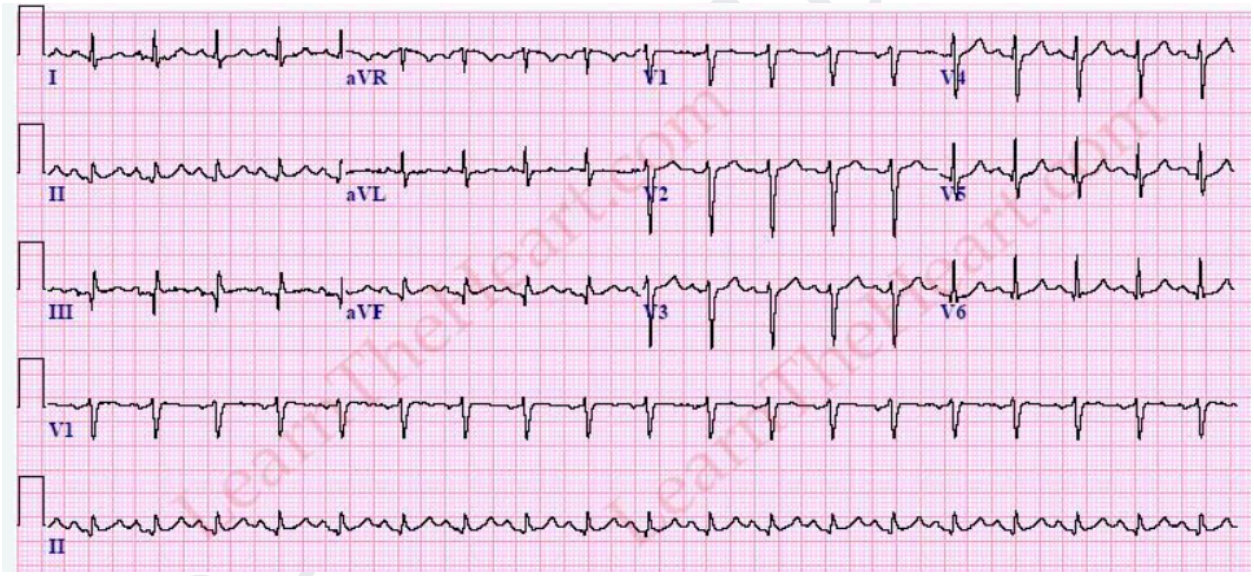

A. Normal sinus rhythm
B. Supraventricular tachycardia
C. Sinus tachycardia
D. Atrial flutter