ECG Basics — Session Review Quiz

Questions: 20
Pass: 70%

1. Which ECG component represents ventricular depolarization?
   A. PR interval
   B. T wave
   C. QRS complex
   D. P wave

2. A normal sinus rhythm originates from which structure?
   A. Bundle branches
   B. Ventricular myocardium
   C. AV node
   D. SA node

3. Which finding is most characteristic of atrial fibrillation?
   A. Regular rhythm with identical P waves
   B. Wide regular complexes at a rapid rate
   C. Irregularly irregular rhythm with no consistent P waves
   D. Slow rhythm with narrow QRS complexes and no P waves

4. A patient has a regular narrow-complex rhythm at 48 beats/minute with a consistent P wave before every QRS. Which rhythm is most likely?
   A. Ventricular bradycardia
   B. Sinus bradycardia
   C. Atrial fibrillation
   D. Junctional escape

5. A regular rhythm has a ventricular rate of 150 beats/minute, narrow QRS complexes, and abnormal or absent visible P waves. Which rhythm is most consistent with these findings?
   A. Junctional tachycardia
   B. Ventricular tachycardia
   C. Normal sinus rhythm
   D. Atrial flutter

Rescue Me Tutoring

6. Which rhythm is most concerning when a patient is pulseless?
A. Supraventricular tachycardia
B. Junctional bradycardia
C. Ventricular tachycardia
D. Sinus bradycardia

7. What does the P wave represent on a normal ECG?
A. Atrial repolarization
B. Ventricular depolarization
C. Atrial depolarization
D. Ventricular repolarization

8. Which feature most strongly supports ventricular tachycardia on an ECG?
A. Irregularly irregular narrow-complex rhythm
B. Wide QRS-complex regular tachycardia
C. Slow narrow-complex rhythm
D. Regular rhythm at 55 beats/minute with normal P waves

9. A patient has an ECG with sawtoothed P waves, a regular narrow QRS rhythm, and atrial rate of 240 beats/minute. Which rhythm is most likely?
A. Atrial fibrillation
B. Supraventricular tachycardia
C. Ventricular tachycardia
D. Atrial flutter

10. Which ECG assessment sequence is most useful when systematically identifying a rhythm?
A. T wave first, then patient history only
B. Rhythm, rate, P waves, PR interval, QRS
C. Rate, rhythm, P waves, PR interval, QRS
D. Blood pressure first, then ignore the ECG

11. What is the ECG interpretation?

Rescue Me Tutoring



A. Normal Sinus Rhythm
B. Supraventricular Tachycardia
C. Sinus Bradycardia
D. Sinus Tachycardia

12. Which finding indicates that an ECG rhythm is regular?
A. Narrow QRS complexes
B. Equal R-R intervals
C. Variable R-R intervals
D. One P wave before every QRS

13. What is the most correct interpretation of this tracing?



A. Wandering Atrial Pacemaker 4: 1
B. Sinus Rhythm with PAC's 4:1
C. Atrial Fibrillation 4:1
D. Atrial Flutter 4:1

14. What is the most correct interpretation of this tracing?



Tutoring

A. Atrial fibrillation
B. Sinus tachycardia
C. Atrial Flutter
D. Ventricular tachycardia

15. True or False. This tracing is regular rhythm.

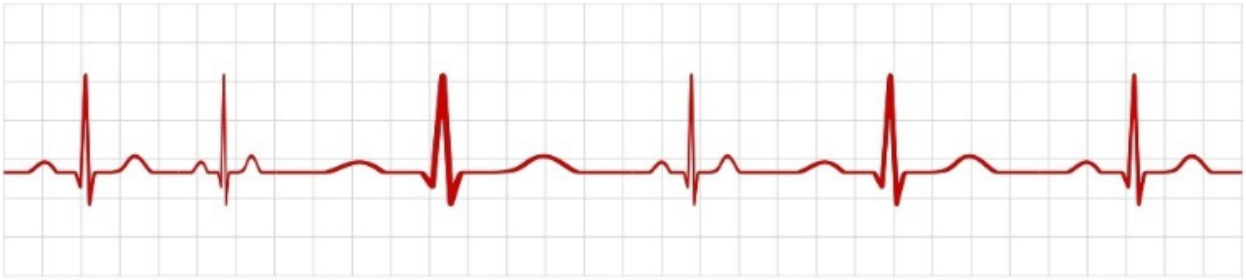

16. Which structure normally delays conduction between the atria and ventricles?
A. SA node
B. Ventricular myocardium
C. Purkinje fibers
D. AV node

17. A patient has a rapid, regular rhythm with wide QRS complexes. Which diagnosis should be strongly considered?
A. Ventricular tachycardia
B. Atrial fibrillation
C. Normal sinus rhythm
D. Sinus bradycardia

18.



What is the rate of the above tracing?
A. 100 bpm
B. 90 bpm
C. 80 bpm

D. 75 bpm

19. Which finding would be most expected in junctional tachycardia compared with normal sinus rhythm?

A. A faster rate with absent, inverted, or retrograde P waves
B. A slower rate with normal P waves before every QRS
C. An irregularly irregular rhythm with no consistent P waves
D. A rapid wide-complex rhythm

20. What is the most correct interpretation of this tracing?



A. Idioventricular
B. Ventricular bradycardia
C. Normal sinus rhythm
D. Accelerated idioventricular

Rescue Me Training