Advanced Cardiac Review

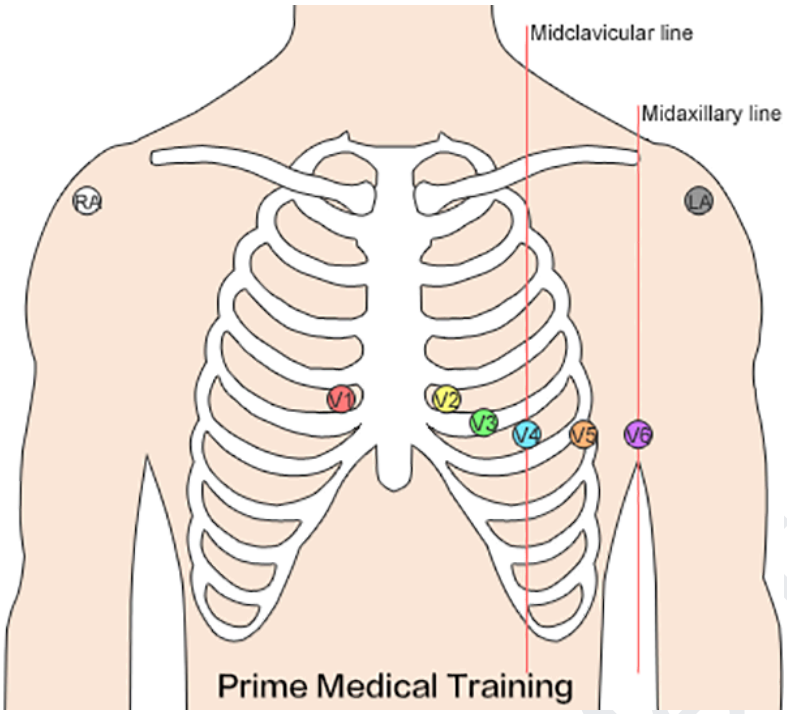

V1- intercostal space 4, right side
V2- intercostal space 4, left side
V3- rib 5
V4- intercostal space 5, left side
V5- rib 6
V6- mid-axillary

Ischemia- depression, reversible with O2
Injury- depression/elevation- need O2
Infarct- elevation

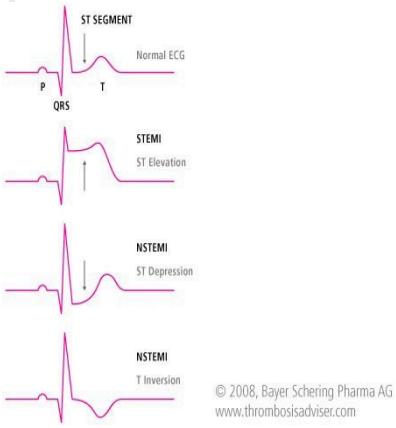

Res Medi tutoring

SALI Method

What leads look at what part of the heart

S- (septal) V1, V2

A- (anterior) V3, V4

L- (lateral) V5, V6, I, avL

I- (inferior) II, III, limb leads, aVF

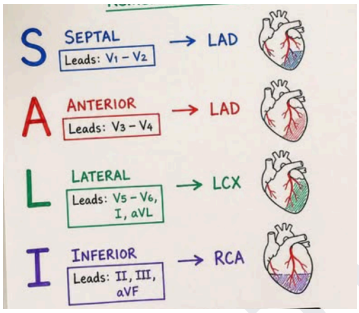

.

Remember the PAILS mnemonic when assessing for reciprocal changes. PAILS stands for P-posterior, A-anterior, I-inferior, L-lateral, S-septal. ST elevations in these leads most commonly create reciprocal ST depressions in the corresponding leads of the next letter in the mnemonic

- Posterior ST Elevation - Anterior ST depression
- Anterior ST Elevation - Inferior ST depression
- Inferior ST Elevation - Lateral ST depression
- Lateral ST Elevation - Septal ST depression
- Septal Elevation - Posterior ST depression

Review

1. A STEMI is presenting in the lateral leads; you would expect reciprocal changes in:

A. V1, V2
B. V3, V4
C. V5, V6
D. II, III

2. You note depression in leads II, III, and aVF, you would expect to see reciprocal changes in the:

A. Posterior view
B. Inferior view
C. Septal view
D. Anterior view

Rescue Me Training

3. There is ST elevation in the inferior leads, you would confirm reciprocal changes in

A. V1, V2
B. V5, V6, I, avL
C. V3, V4
D. II, III, limb leads, aVF

STEMI & NSTEMI — Acute Coronary Syndromes

Basic A&P

The coronary arteries supply oxygenated blood to the myocardium (heart muscle).

The major coronary arteries include:

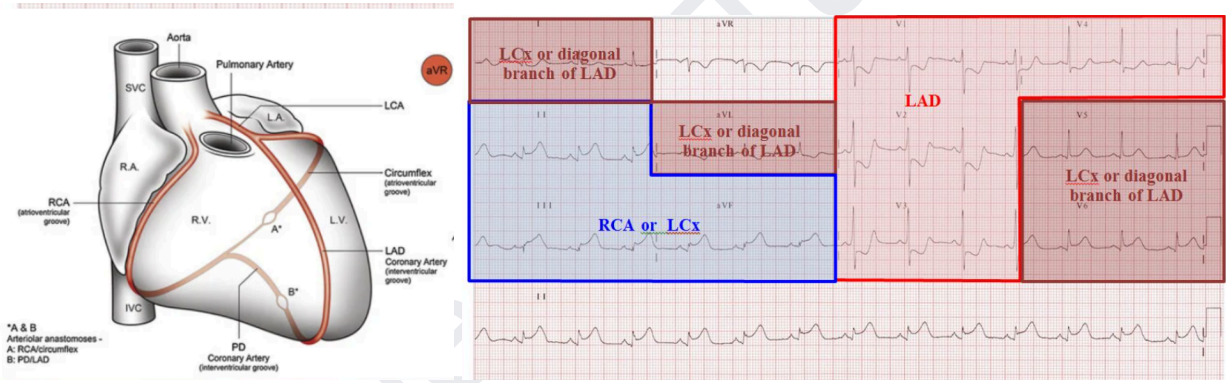

- Inferior Wall (Leads II, III, and aVF): Look at the bottom surface of the heart and primarily correspond to the Right Coronary Artery (RCA), or occasionally the left circumflex in certain individuals.
- Anterior Wall and Septum (Leads V1 through V4): Look at the front wall and the muscular wall dividing the ventricles; these map directly to the Left Anterior Descending (LAD) artery.
- Lateral Wall (Leads I, aVL, V5, and V6): Look at the side/left wall of the heart and correspond to the Left Circumflex (LCx) artery or diagonal branches of the LAD.
- Posterior Wall (V1 through V3 for reciprocal changes, or V7 through V9 directly): Does not have direct standard frontal/anterior views, so clinicians look for reciprocal tall R-waves and ST depression in leads V1–V3, which

typically point to involvement of the Right Coronary Artery (RCA) or Left Circumflex (LCx).

When a coronary artery becomes narrowed or blocked, myocardial oxygen supply decreases.

Prolonged ischemia → myocardial cell injury → myocardial necrosis (infarction).

Review

1. A patient has ST-segment elevation in leads II, III, and aVF. Which coronary artery is most commonly associated with this ECG pattern?

A. Left anterior descending (LAD)
B. Right coronary artery (RCA)
C. Left circumflex (LCx)
D. Left main coronary artery

Answer: B — Right coronary artery (RCA)

Rationale: Leads II, III, and aVF view the inferior wall of the heart. Inferior STEMIs are most commonly associated with RCA occlusion, although the LCx can also supply the inferior wall.

---

2. ST-segment elevation is present in leads V1–V4. Which coronary artery is most likely involved?

A. Right coronary artery
B. Left circumflex artery
C. Left anterior descending artery
D. Posterior descending artery

Answer: C — Left anterior descending artery (LAD)

Rationale: V1–V4 primarily view the septal and anterior portions of the heart. The LAD is the major coronary artery associated with this territory.

Rescue Me Tutoring

3. A patient's 12-lead ECG shows ST-segment elevation primarily in leads I, aVL, V5, and V6. Which coronary artery is most likely involved?

A. Left circumflex artery
B. Right coronary artery
C. Left anterior descending artery
D. Right marginal artery

Answer: A — Left circumflex artery (LCx)

Rationale: Leads I, aVL, V5, and V6 are associated with the lateral wall. The LCx commonly supplies this territory.

---

4. A patient has ST-segment elevation in leads V7, V8, and V9. Which coronary artery is most commonly associated with this finding?

A. Left anterior descending artery
B. Right coronary artery
C. Left circumflex artery
D. Left main coronary artery

Answer: C — Left circumflex artery (LCx)

Rationale: V7–V9 are posterior leads and assess the posterior wall. Posterior MI is commonly associated with LCx occlusion, although the RCA can also be responsible.

STEMI

ST-Elevation Myocardial Infarction

A STEMI occurs when there is usually a complete or near-complete coronary artery occlusion, resulting in significant myocardial ischemia and injury.

ECG

Rescue Me Tutoring

The classic finding is:

ST-segment elevation in two or more anatomically contiguous leads.

The ECG changes occur because ischemic/injured myocardium produces abnormal electrical activity.

Common presentation

Patients may experience:

- Chest pressure, heaviness, or discomfort
- Pain radiating to the arm, shoulder, jaw, back, or neck
- Dyspnea
- Diaphoresis
- Nausea/vomiting
- Pallor
- Anxiety or a feeling of impending doom

Important: Presentation can be atypical, particularly in women, older adults, and patients with diabetes.

Women presentation: Nausea/vomiting, pain between the shoulder blades

Diabetic presentation: Uncomfortable, nausea/vomitting, low back pressure

Think:

STEMI = acute coronary occlusion + ST elevation + time-sensitive reperfusion.

This is a time-critical emergency. Rapid recognition, 12-lead ECG acquisition, appropriate treatment, and transport toward definitive coronary intervention are priorities according to local protocols.

NSTEMI

Non-ST-Elevation Myocardial Infarction

Rescue Me Tutoring

An NSTEMI is also a myocardial infarction, but it does not produce the classic ST elevation seen in STEMI.

The coronary artery is often partially obstructed, although the underlying coronary pathology can vary.

ECG

Possible findings include:

- ST-segment depression
- T-wave inversion
- Nonspecific changes
- Or sometimes no obvious ischemic ECG changes

Troponin

A key distinction is:

NSTEMI → myocardial injury → elevated cardiac troponin.

Troponin is released into the bloodstream when myocardial cells are damaged.

Symptoms

NSTEMI can present similarly to STEMI:

- Chest pressure/discomfort
- Dyspnea
- Diaphoresis
- Nausea
- Radiation of discomfort
- Weakness or fatigue

You cannot rule out NSTEMI simply because the ECG doesn't show ST elevation.

Rescue Me Tutoring

STEMI vs. NSTEMI — Quick Comparison

	STEMI	NSTEMI
Coronary problem	Usually complete/near-complete occlusion	Often partial occlusion
Myocardial injury	Yes	Yes
Troponin	Elevated	Elevated
ST elevation	Typically present	Absent
ST depression/T-wave changes	May occur	May occur
Medical emergency	Yes — time critical	Yes
Main concern	Rapid reperfusion	Prevent progression and manage ischemia

STEMI = ST elevation + infarction

NSTEMI = No ST elevation + infarction

Both are myocardial infarctions. The absence of ST elevation does not mean the patient is having a less serious cardiac emergency.

Review

1. Which ECG finding is most characteristic of a STEMI?

A. ST-segment depression in one lead
B. Prolonged PR interval
C. Widened QRS complex
D. ST-segment elevation in anatomically contiguous leads

Answer: D

Rescue Me Tutoring

Rationale: STEMI is characterized by acute myocardial injury producing ST-segment elevation in anatomically related/contiguous leads.

---

2. A patient has chest pressure, diaphoresis, and nausea. Their 12-lead ECG shows ST depression and T-wave inversion. Cardiac troponin is elevated. Which condition is most likely?

A. NSTEMI
B. STEMI
C. Stable angina
D. Sinus tachycardia

Answer: A

Rationale: NSTEMI involves myocardial infarction with elevated troponin but without the characteristic ST-segment elevation of STEMI.

---

3. Why does myocardial infarction cause an elevation in cardiac troponin?

A. The SA node releases excess troponin during tachycardia
B. Damaged myocardial cells release troponin into the bloodstream
C. The liver produces troponin during sympathetic stimulation
D. Coronary arteries release troponin when they constrict

Answer: B

Rationale: Troponin is found within cardiac muscle cells. Myocardial injury causes troponin to enter the bloodstream, making it an important marker of myocardial injury.

---

4. Which statement BEST differentiates STEMI from NSTEMI?

A. STEMI causes chest pain while NSTEMI does not
B. NSTEMI does not involve myocardial injury

Rescue Me Tutoring

C. STEMI typically demonstrates ST-segment elevation, while NSTEMI does not
D. STEMI has normal troponin levels while NSTEMI has elevated levels

Answer: C

Rationale: Both STEMI and NSTEMI involve myocardial injury and typically elevated troponin. The major ECG distinction is the presence of characteristic ST-segment elevation in STEMI.

Case Study 1 —

Patient: 58-year-old male
Chief Complaint: "I have crushing chest pain."

History:
You arrive to find the patient sitting upright on the couch, pale and visibly anxious. He reports sudden onset of central chest pressure approximately 35 minutes ago while carrying groceries. The pain is 8/10, described as heavy pressure, and radiates into his left arm and jaw.

He reports nausea and sweating. He denies previous cardiac events.

Medical History:

- Hypertension
- Hyperlipidemia
- Smokes 1 pack/day
- No known medication allergies

Medications:

- Ramipril
- Atorvastatin

Vital Signs:

- HR: 96/min
- BP: 154/92 mmHg
- RR: 20/min

Rescue Me Tutoring

- SpO_2: 95% RA
- Temp: 36.7°C
- Skin: Pale, cool, diaphoretic

Assessment:
Airway patent. Respirations regular with clear lung sounds bilaterally. Radial pulse regular and strong. Patient remains alert and oriented.

12-lead ECG:

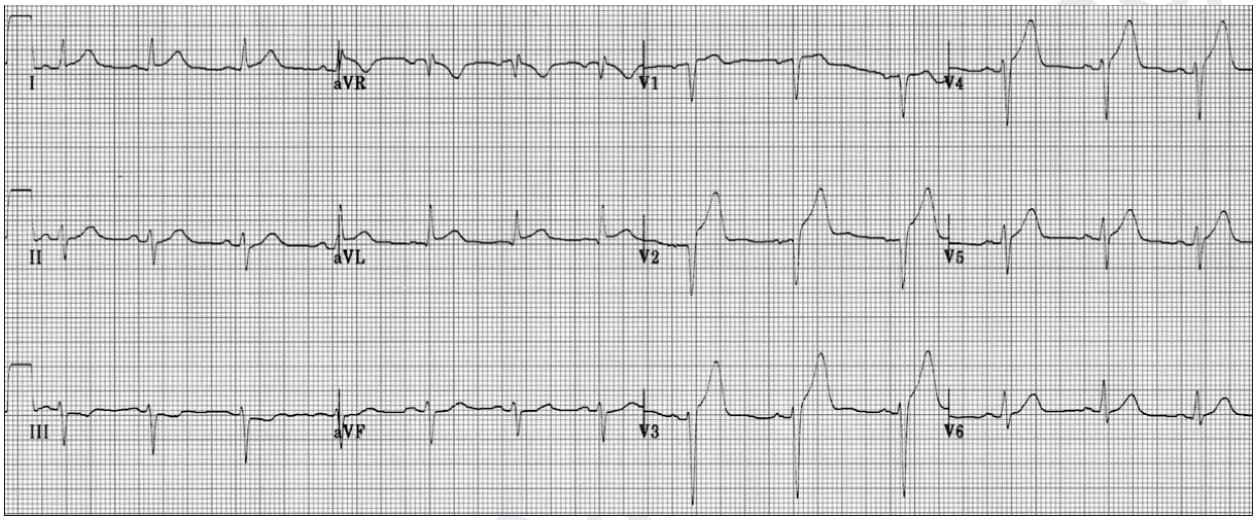

Questions:

1. What abnormalities are present on the ECG?
2. Which coronary artery territory is most likely involved? Left Anterior Descending (LAD)
3. What additional ECG leads could you consider?
4. What is your priority management for this patient?

Case Study 2 —

Patient: 67-year-old female
Chief Complaint: “I feel sick and dizzy.”

History:
The patient developed sudden nausea, weakness, and dizziness while eating

breakfast. She denies significant chest pain but states she has “a strange pressure” in her upper abdomen.

She appears pale and sweaty. Her husband reports that she briefly complained of discomfort between her shoulder blades.

Medical History:

- Type 2 diabetes
- Hypertension
- Previous angina

Medications:

- Metformin
- Ramipril
- ASA

Vital Signs:

- HR: 52/min
- BP: 88/56 mmHg
- RR: 18/min
- SpO_2: 94% RA
- Temp: 36.5°C
- Skin: Cool and diaphoretic

Assessment:
Patient is alert but complains of dizziness. Lung sounds are clear bilaterally. Peripheral pulses are weak but palpable.

Rescue Me Tutoring

12-lead ECG:

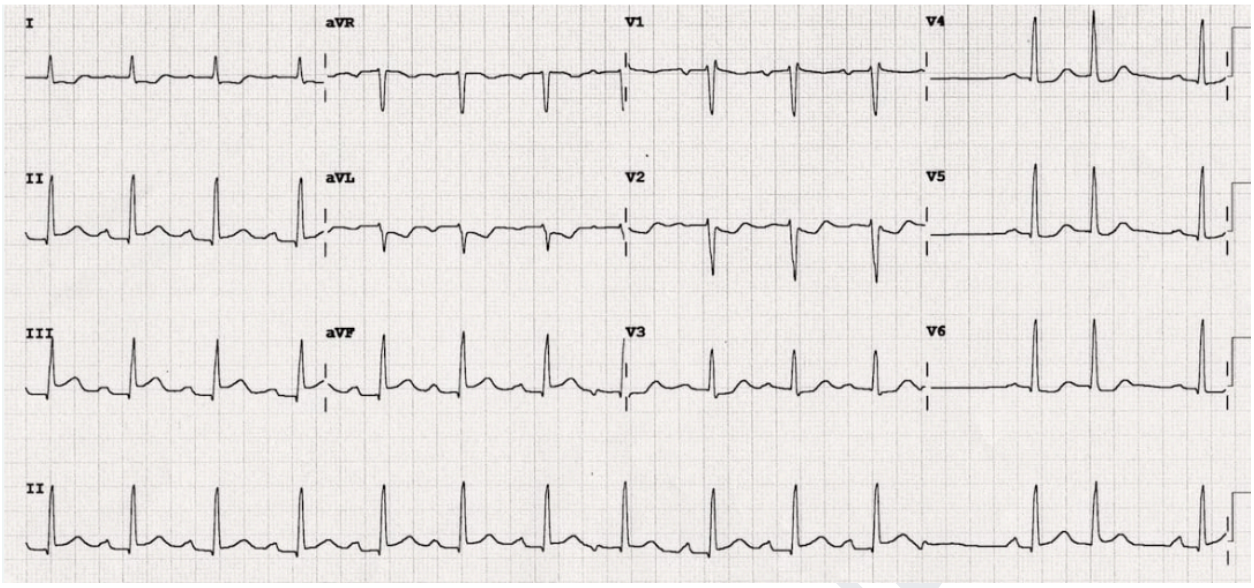

Student Questions:

1. What does the ECG demonstrate? Inferior right side
2. Which wall of the heart appears to be affected? right
3. Which coronary artery is commonly associated with this territory? Right Coronary Artery (RCA)
4. Based on the patient's presentation, what additional ECG leads should be considered?

Case Study 3 —

Patient: 49-year-old male
Chief Complaint: "I can't catch my breath."

History:
The patient developed sudden shortness of breath and chest pressure while shovelling snow. He describes the discomfort as 6/10 and says it feels like "someone is sitting on my chest."

He is nauseated and extremely anxious. Pain began approximately 20 minutes before EMS arrival.

Rescue Me Tu

Medical History:

- Hypertension
- Family history of coronary artery disease
- Smoker

Medications:

- Amlodipine

Vital Signs:

- HR: 108/min
- BP: 168/96 mmHg
- RR: 26/min
- SpO_2: 91% RA
- Temp: 36.8°C
- Skin: Pale and diaphoretic

Assessment:
Airway patent. Increased work of breathing. Lung sounds initially clear bilaterally. Patient is alert and oriented.

12-lead ECG:

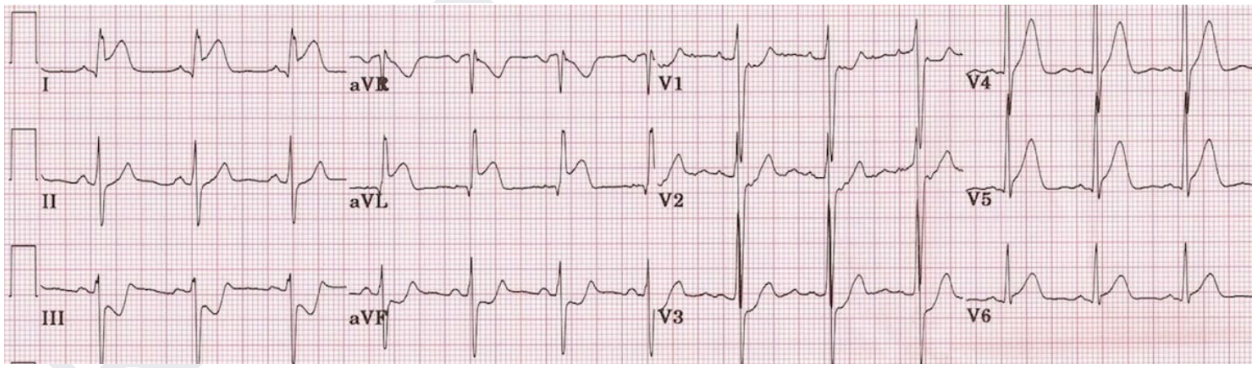

Student Questions:

1. Identify the leads showing the primary ECG changes.
2. What area of the myocardium do these leads represent? Lateral STEMI
3. Which coronary artery is most commonly associated with this territory?
4. What additional assessment findings would increase your suspicion of an acute coronary occlusion?

Me Tutoring

Case Study 4 —

Patient: 61-year-old male
Chief Complaint: “The pain is going through to my back.”

History:
The patient developed sudden severe chest pressure while watching television. The pain is 9/10 and radiates directly through to his upper back. He is nauseated and diaphoretic.

He states the pain started approximately 45 minutes ago.

Medical History:

- Previous MI 5 years ago
- Hypertension
- Hyperlipidemia

Medications:

- Atorvastatin
- Ramipril
- ASA

Vital Signs:

- HR: 88/min
- BP: 142/86 mmHg
- RR: 22/min
- SpO_2: 94% RA
- Temp: 36.6°C
- Skin: Cool and diaphoretic

Assessment:
Airway patent. Respirations slightly increased but lung sounds are clear. Patient is alert and oriented. Peripheral pulses present bilaterally.

Rescue Me Tutoring

12-lead ECG:

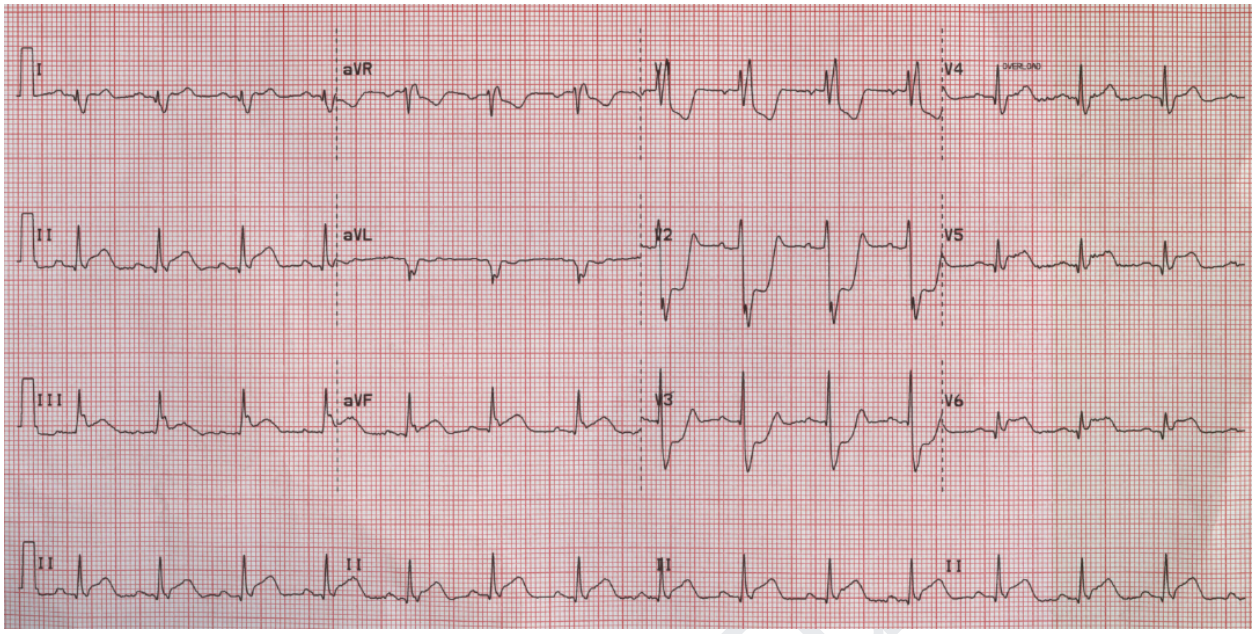

Student Questions:

1. What findings do you see on the 12-lead?
2. Which leads should you examine for reciprocal changes? posterior
3. What additional leads should you obtain? V4- v7 v5 v8 v6 v9
4. Which coronary artery is commonly associated with posterior involvement? Right Coronary Artery (RCA) or Left Circumflex (LCx).
5. How would the patient's clinical presentation support your ECG interpretation?

Rescue Me Tu