Cardiac Emergencies

Signs and symptoms that are expected with cardiac emergencies: undefined chest pain, SOB, diaphoretic, increased WOB (these are not specific; watch for indicators)

Dysrhythmias= bad rhythm Arrhythmias= abnormal rhythm

WHAT	WHERE	WHY	INDICATOR	TX	PROGRESSION	ECG/ETCO2
Atherosclerosis			History, increased BP			Norm/ Norm
Arteriosclerosis	Lumen		High blood pressure			Norm/ Norm
HTN- Hypertensive Emergency **RAMIPRIL ***	Arteries				Stroke, seizure, MI- cardiac arrest, pulmonary embolism	
Aortic Aneurysm= widening	Aortic arch/descending aorta			IV, ECG, O2 to maintain above 94%, ALS -Morphine		Norm- Tachy, ST Depression/ Low CO2
Acute Aortic Dissection = tear						
Ruptured AAA	Typically descending				Hypovolemic shock, cardiogenic shock,	Tachy, dysrhythmia

Rescue Me Tutoring

	aorta				cardiac arrest	s, VTach-VFib/ Low CO2 or High CO2
Stable Angina		Spasms in coronary arteries/ exertional				
Unstable Angina	Coronary arteries					ST depression in the inferior leads/ Low CO2
Prinzmetal Angina					Decreased blood flow, increased hypoxia, unstable angina, MI, Heart blocks	
Myocardial Infarction	Coronary arteries	Sudden or total occlusion			Cardiac arrest	
Left-sided heart failure		HTN, MI		Goal: Pre-oxygenation, POC, if BP is good, sit up with legs dangling, O2 to maintain 90-94%, IV TKVO,		

Rescue Me Tutoring

				ECG, local protocol for NTG **No Lasix- induces hypokalemia, dysrhythmia,** CPAP		
Right-sided heart failure		Pulmonary HTN, Pulmonary embolism			Congestive heart failure- cardiogenic shock, cardiac arrest	
Cardiac tamponade	Trauma to heart				Cardiac Arrest	Tachy/ Low CO2
Endocarditis				POC, IV, ECG, O2 to maintain 94% , Antibiotics		
Myocarditis	Heart wall muscle					
Pericarditis					Heart Failure, Sepsis, Cardiogenic Shock	

Rescue Me Tutoring

Pulsus paradoxus= systolic drop by 10mmHg or weak pulse on inspiration
Atropine: ALS drug -increases heart rate
Transcutaneous pacing: ALS procedure- rate 60-80. Indication: symptomatic bradycardia
Cardioversion: ALS procedure- indication: unstable tachycardia, SVT

Ischemia- depression, reversible with O2
Injury- depression/elevation- need O2
Infarct- elevation

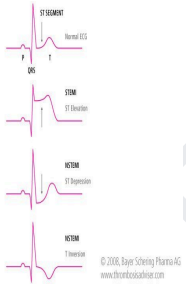

<u>SALI mnemonic and when to use it</u>
What leads look at what part of the heart

- S- (septal) V1, V2
- A- (anterior) V3, V4
- L- (lateral) V5, V6, I, avL
- I- (inferior) II, III, limb leads, avF

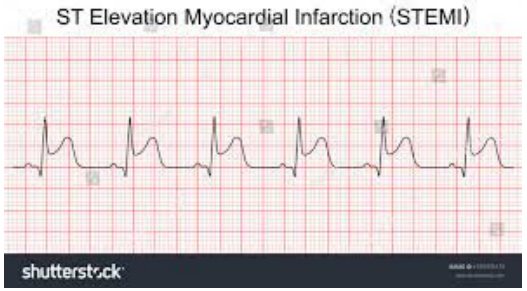

To confirm a true STEMI, you need elevation in 2 or more leads.
Each small box is 0.04 seconds; one larger box is 0.20 seconds

<u>PAILS mnemonic and when to use it</u>
Remember the PAILS mnemonic when assessing for reciprocal changes. (Reciprocal- think opposite)
PAILS stands for P-posterior, A-anterior, I-inferior, L-lateral, S-septal. ST elevations in these leads most commonly create reciprocal ST depressions in the corresponding leads of the next letter in the mnemonic

- Posterior ST Elevation - Anterior ST depression
- Anterior ST Elevation - Inferior ST depression
- Inferior ST Elevation - Lateral ST depression
- Lateral ST Elevation - Septal ST depression
- Septal Elevation - Posterior ST depression

Rescue Me Tutoring

Common COPR tested ECGS
Atrial Fibrillation
Ventricular Fibrillation
Ventricular Tachycardia
Idoventricular
Sinus bradycardia and SVT
Atrial Flutter
Heart blocks,
Bundle Branch Blocks
Ectopics beats

3-lead placement: Remember: White on the right, green to the ground (white over green), smoke over fire (black over red)
White: upper right midclavicular
Green: right side abdomen
Red: left abdomen
Black: left upper midclavicular

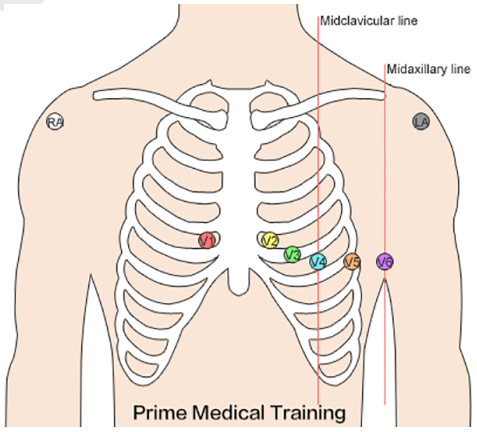

3-lead to 12-lead placement
White: right wrist
Green: right ankle
Red: left ankle
Black: left wrist
V1: intercostal space 4, right side
V2: intercostal space 4, left side
V3: rib 5
V4: intercostal space 5, left side
V5: rib 6
V6: mid-axillary

Rescue Me Tutoring